

## Research Article

# Subperiosteal Schwannoma: A Rare Cause of Unexplained Pain Around the Knee

 Bishnu Prasad Patro,<sup>1</sup>  Sudhanshu Sekhar Das,<sup>1</sup>  Sudarsan Behera,<sup>1</sup>  Gantagaru Amrit,<sup>1</sup>  
 Saroj Kumar Patra,<sup>2</sup>  Doki Sunil Kumar<sup>1</sup>

<sup>1</sup>Department of Orthopaedics, AIIMS Bhubaneswar Sijua, Patrapada, Odisha, India

<sup>2</sup>Department of Trauma and Emergency, AIIMS Bhubaneswar Sijua, Patrapada, Odisha, India

### Abstract

**Objectives:** Bone surface is supplied with ample numbers of both sensory and sympathetic nerves, despite this a very few cases of Schwannoma had been reported to be originating from subperiosteal region. Our study aims at retrospectively analysing patients presenting with vague pain around the knee joint with inconclusive radiological features in whom subperiosteal Schwannoma was being considered as a differential diagnosis.

**Methods:** Three patients presented with vague pain around knee joint to our OPD over a 10 years period. Two patients had a painful mass around knee. Pain was temporarily relieved with NSAIDs. Two patients had lesion in proximal tibia and one on distal femur. All patients were subjected to excisional biopsy and the results were analysed.

**Results:** X ray was unremarkable in all three patients. Hypochoic lesion was found on ultrasonography suspected to be benign neoplastic lesion. Histopathology study of all excisional biopsy specimens confirmed the diagnosis of schwannoma. All patients recovered uneventfully and had complete relief of pain post excision. There has not been any incidence of recurrence.

**Conclusion:** In patients with diffused pain around knee, subperiosteal schwannoma should be kept as one of the differential diagnosis. USG can help in diagnosis subperiosteal schwannoma.

**Keywords:** Knee pain, schwannoma, subperiosteal

**Cite This Article:** Patro BP, Das SS, Behera S, Amrit G, Patra SK, Kumar DS. Subperiosteal Schwannoma: A Rare Cause of Unexplained Pain Around the Knee. *EJMO* 2020;4(1):54–59.

The most common benign tumors of the peripheral nerve are neurofibromas and schwannomas.<sup>[1]</sup> Of these, schwannomas are relatively rare compared to neurofibromas.<sup>[2]</sup> The tumors develop from the Schwann cells that cover most of axon in all peripheral nerves.<sup>[3]</sup> Schwann cells originate from neural crest cells and are responsible for the creation and perpetuation of the myelin sheath.<sup>[3]</sup> A typical schwannoma is a benign, solitary, encapsulated lesion that can develop on any peripheral nerve of the body.<sup>[4]</sup> Schwannomas rarely become malignant.<sup>[5,6]</sup> In neurofibromatosis type 2 disorder, schwannomas may involve multi-

ple peripheral nerves.<sup>[7]</sup> Schwannomas involving the bone are infrequently encapsulated.<sup>[8]</sup>

Benign schwannomas are not common in the general population. They tend to develop on sensory nerves; this tendency has been attributed to the fact that sensory nerves have the highest schwann cell to axon ratio.<sup>[8]</sup> Schwannomas often arise in the soft tissue of the head and neck which have a dense network of sensory nerves.<sup>[9]</sup> Approximately 25%–40% of all cases of schwannomas involve the head and neck.<sup>[10,11]</sup> However, these benign tumors can develop on any bone; in fact, schwannomas account for <0.2% of all

**Address for correspondence:** Sudarsan Behera, MD. Department of Orthopaedics, AIIMS Bhubaneswar Sijua, Patrapada, Odisha, India

**Phone:** 9692296970 **E-mail:** sudarsanctc@gmail.com

**Submitted Date:** September 27, 2019 **Accepted Date:** January 06, 2020 **Available Online Date:** March 12, 2020

©Copyright 2020 by Eurasian Journal of Medicine and Oncology - Available online at [www.ejmo.org](http://www.ejmo.org)

**OPEN ACCESS** This work is licensed under a Creative Commons Attribution-NonCommercial 4.0 International License.



primary bone tumors.<sup>[8,12]</sup> The mandible is the most common site for schwannomas followed by the sacrum.<sup>[8,13]</sup> The tendency of schwannomas to develop in these sites is because of the sensory mandibular nerve passing through the long osseous canal and the large number of sensory nerves passing through multiple sacral foramina.<sup>[8]</sup>

Typically, schwannomas are slow growing, small (usually <3 cm), tender, soft masses, mobile in the coronal plane.<sup>[2,4]</sup> However, intraosseous schwannomas do not often present with palpable mass and only cause vague pain due to nerve irritation.<sup>[14]</sup> Schwannomas and neurofibromas have almost similar clinical, radiological and histological features with only subtle differences. Depending upon the site, size and chronicity of the lesion, schwannomas may show no change to mild periosteal reaction to scalloping of the cortex on a plain radiograph.<sup>[15-17]</sup> As has been mentioned earlier, Schwannomas can develop in any peripheral nerve in any extremity; but for unknown reasons, they grow mostly in the flexor aspect of upper limbs.<sup>[2,4,14]</sup> It is rare to find a case of symptomatic schwannomas in the lower extremities.<sup>[18]</sup> In spite of the fact that the periosteum has a rich supply of sensory nerves, schwannomas have been scarcely found on the surface of the bone. Knight et al.<sup>[4]</sup> reported that only 4 schwannomas out of 234 occur in muscles or the surface of the bone.

In the current review, we present three patients with chronic pain around the knee joint. All the three patients had been typically managed for an extended period of time with NSAIDs (nonsteroidal anti-inflammatory drugs) with only temporary relief of symptoms. On further radiological evaluation, we suspected the presence of juxtacortical lesions in all three cases. An excision biopsy taken from the patients found the lesions to be neurilemmomas. With excision of the mass, pain completely subsided in all three

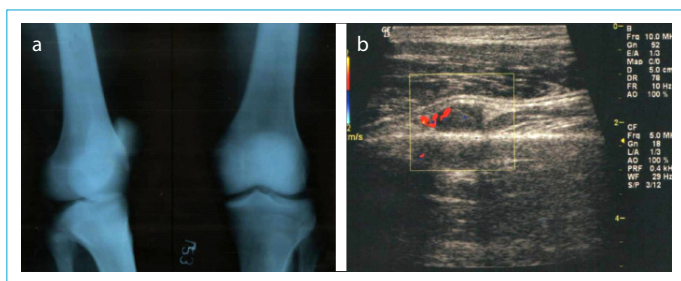
cases. There has been no recurrence of symptoms even after 3–5 years of follow-up.

## Methods

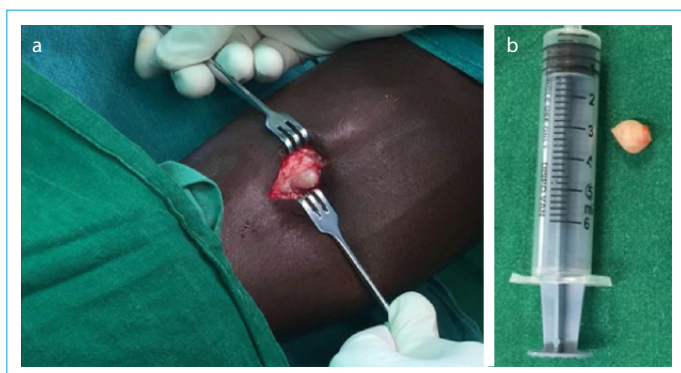
Over a period of 10 years, we received three patients, all male, with similar complaints of vague pain around the knee. All the three patients had symptoms for more than a year (Table 1). One patient had to quit his job due to pain and constant discomfort. Medical examination and routine blood investigations were unremarkable and none of the patients had a history of any significant trauma. All had been using NSAIDs, either oral or injectable, for a prolonged period of time with only temporary relief of symptoms. The knee range of motion was normal for all the three patients. The patient with lesion on the tibia presented with painful mass (n=2) and the patient with lesion on the thigh presented only with pain (n=1). On local examination, both patients had a smooth regular mass with well-defined margins on the anterior aspect of the leg. The mass, was firm in consistency and slightly mobile; it did not adhere to the skin and was tender on palpation. Radiograph of the knee was unremarkable (Fig. 1a). Ultrasonography (USG) showed a well-delineated 1.24 cm hypoechoic soft tissue mass on the medial aspect of the thigh overlying the left femur in the first patient (Fig. 1b) and a similar mass of size 2 cm and 1 cm respectively overlying the tibia in the other two patients; there was no calcification, cystic change, increased vascularity or bony erosion. The USG features were suggestive of a benign lesion; hence, we planned for an excisional biopsy. Intraoperatively, we found a small glistening round to oval mass underlying the periosteum, free from the bony cortex (Fig. 2a). The excised mass (Fig. 2b) was sent for histopathological examination. Histopathology study revealed the mass to be schwannoma with classi-

**Table 1.** Characteristics of patients with regard to age, sex, presentation, radiograph, operation, complication and biopsy

Case no	1	2	3
Age	35	30	45
Sex	Male	Male	Male
Site	Femur (left)	Tibia (left)	Tibia (Right)
Time since presentation (in months)	24	18	14
Presenting symptoms	Pain	Painful lump	Painful lump
Year of presentation	2008	2015	2016
Imaging study	Radiograph-normal USG-well defined hypoechoic lesion	Radiograph-normal USG-well defined hypoechoic lesion	Radiograph-normal USG-well defined hypoechoic lesion
Size on USG (in mm)	1.24×0.64×0.5	2×1×0.6	1×0.7×0.5
Treatment	Excision+send for biopsy	Excision+send for biopsy	Excision+send for biopsy
Recurrence or complication	Nil	Nil	Nil
Biopsy report	Neurilemmoma	Neurilemmoma	Neurilemmoma



**Figure 1.** (a) Plain photograph of the distal thigh with knee showing no abnormality; (b) USG thigh Of review only patient 1 showing a well differentiated hypoechoic lesion arising outside the bone cortex elevating the periosteum.



**Figure 2.** (a) Intraoperative Photograph Showing Round Glistening Whitish Mass Free From Cortex; (b) The Mass After Excision (Patient 2).

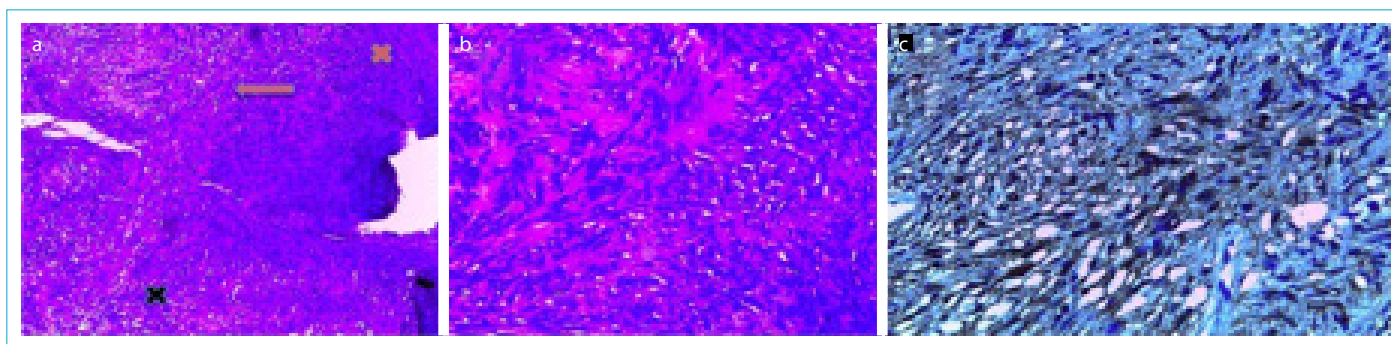
cal Antoni A and Antoni B areas and verocay bodies (Fig. 3a, b). Immunohistochemistry with S100 (Fig. 3c) was strongly positive which further reinforced the diagnosis. All three patients had immediate relief of symptoms post excision and no recurrence has been documented in either of them till the latest follow-up.

## Discussion

Schwannoma is a benign tumor of the nerve sheath.<sup>[1]</sup> In 1908, Verocay was the first to identify this distinct tumor;

he termed it neurinoma.<sup>[13]</sup> Since then, various terms, such as neurilemmas, neurocytomas and peripheral gliomas, have been used to describe neurinomas.<sup>[18]</sup> Schwannomas are relatively uncommon soft tissue tumors and Kransdorf<sup>[19]</sup> reported that they constitute approximately 0.2% of a total of 39,179 tumors. Distribution of schwannomas in the lower extremities has a varied presentation among large series (which include >100 cases) ranging from 13.5%–38.5%.<sup>[20,4,14]</sup> However, all of our patients had lesion in the lower limb; considering that these were just three cases, our percentage may be only a matter of chance. Schwannomas rarely develop in or near the bone surface and the suggested mechanisms of growth includes the following:<sup>[11]</sup> (a) They may develop from nerves traversing through the osseous canal; (b) They may develop from small nerves accompanying the nutrient vessels; (c) They may develop in soft tissues in the nearby vicinity and secondarily erode the bone or develop from nerves supplying the periosteum. Among osseous schwannomas, periosteal ones are the least common and have been described only in a few case reports (Table 2).<sup>[16,17,21,22]</sup> To our knowledge, the current series of three cases of subperiosteal schwannoma is the largest series to have been ever reported and we believe we are the first to describe two such cases on the tibial surface.

Age is an exception to schwannoma in the bone; there have been reports of a child as young as 9 years<sup>[8]</sup> and an adult as old as 56 years developing schwannoma in the bone.<sup>[8]</sup> However, schwannomas are more common in the third and fourth decade of life.<sup>[18]</sup> Isolated reports of subperiosteal schwannoma have been reported in the age group of 18 years–34 years (Table 2). In our series, all three patients were aged 30–45 years. Schwannomas affect either sex equally without any clear sex predominance.<sup>[8,14,18,20]</sup> Incidentally, all the patients in our study were male. Soft tissue schwannomas most commonly present as round to oval masses with or without pain.<sup>[2,4,14,20]</sup>



**Figure 3.** (a) Photomicrograph (H & E study, 100X) showing Antoni A area (Red cross) and Antoni B (Black cross) and Nuclear Pallisading pattern (Verocay bodies, Red Arrow); (b) Photomicrograph (H & E study, 400X) showing Verocay bodies; (c) Photomicrograph (S 100 staining, 400X) showing diffusely positive nuclear and cytoplasmic pattern.

**Table 2.** Previous reports of subperiosteal schwannomas

Authors	Age	Sex	Location	Periosteal reaction	Presenting symptoms	Time since presentation	Imaging study
Lhedan FA <sup>[21]</sup>	18	Female	Femur	Present	Painless lump	Long duration (not mentioned)	Benign bone tumor
Verma RR et al. <sup>[16]</sup>	38	Male	Femur	Absent	Pain with no swelling	4 years	Smooth scalloping of the cortex
Singh V et al. <sup>[22]</sup>	28	Female	Ulna	Absent	Painful swelling	Long duration (duration not mentioned)	Cystic lesion with well-defined sclerotic margin
Lakhotia et al. <sup>[17]</sup>	34	Male	Pelvis	Absent	Pain with no swelling	3 months	Ill-defined lytic lesion

Occasionally, they are associated with weakness, paraesthesia and a positive Tinel's sign.<sup>[4,14,18]</sup> Subperiosteal schwannomas however have varied presentation such as painless lump,<sup>[21]</sup> vague pain without any swelling<sup>[16,17]</sup> and painful swelling.<sup>[22]</sup> A feature common to our cases were that they all presented late to the physician, with duration of symptoms ranging from 3 months to 4 years.<sup>[16,17,21,22]</sup> Two of our patients presented with a painful lump on the tibia; the patient with lesion on the femur had only pain. All presented to us after having symptoms for at least 14 months. The spectrum of lesions that appear on the bone surface are large and may pose a diagnostic challenge as they all present with similar tumor and tumor-like symptoms.<sup>[23,24]</sup> The most common tumors are neurofibroma, periosteal osteoid osteoma, periosteal osteosarcoma, osteochondroma, periosteal chondroma, subperiosteal hematoma, reactive periostitis, fibrous cortical defect, periosteal ganglion, lipoma, etc. Andrew et al. have also described a single case of juxtacortical malignant schwannoma (malignant peripheral nerve sheath tumor, MPNST). Schwannoma is one of the rarest lesions to appear on the bone surfaces.<sup>[25]</sup>

Plain radiograph of these lesions is usually unremarkable. In some cases, focal bony scalloping may be seen indicating the benign nature of the lesion.<sup>[26]</sup> In our series, all three patients had a normal radiograph. Ultrasonography (USG) is the first line of investigation and we followed the same line of investigation.<sup>[18]</sup> A schwannoma is characterized by a well-defined hypoechoic, ovoid lesion in continuity with the originating nerve and sometimes with increased vascularity and notable arterial flow;<sup>[26]</sup> these features are shared by neurofibroma and MPNST. Due to this overlapping of radiological features, it is not always possible to differentiate between neurofibroma, schwannoma and MPNST<sup>[29]</sup> without a histological study. Thus, USG cannot reliably differentiate between neurofibroma and schwannoma of the extremities.<sup>[27]</sup> On magnetic resonance imaging, PNST exhibits low signal intensity on T1W images and high sig-

nal intensity on T2W images.<sup>[28]</sup> The so-called "target sign," which is a non-enhancing focus seen commonly in T2W images, and the "split fat sign," which shows the presence of fat surrounding the lesion in T1W images, is present in both neurofibroma and schwannoma but absent in MPNST.<sup>[29]</sup> Though compared to USG, MRI has a better tissue characterization, USG is more accurate than MRI in detecting lesions in the peripheral nerve.<sup>[30]</sup> It is also relatively safe, inexpensive and a widely available investigation. Considering the fact that MPNST on the bone surface is extraordinarily rare and that the clinical and radiological picture in all three of our patients were benign, we did not feel the need of MRI in any of our cases and directly went for excision of the lesion. Moreover, MRI would not have changed the further course of management i.e excision and biopsy.

Symptomatic schwannoma are surgically excised and recurrence after complete surgical excision is unknown.<sup>[7,18]</sup> The microscopic features of a schwannoma are fairly consistent and consist of two kind of tissues, Antoni A and Antoni B. Antoni A areas are characterized by closely packed spindle shaped cells with prominent nuclear palisading (verocay bodies) and Antoni B areas are composed of loosely packed schwann cells with intervening myxoid stroma.<sup>[4,8,14,31]</sup> Traditional haematoxylin and eosin (H&E) staining can differentiate between schwannoma, neurofibroma and MPNST<sup>[14]</sup> but in doubtful cases, immunohistochemistry markers can be tested. In particular, immunostaining for S100 and collagen type IV is strongly positive for schwannoma but weakly positive and sometimes negative for neurofibroma and MPNST.<sup>[8,14,31]</sup> In all three of our cases, conventional H&E staining demonstrated classical features of schwannoma and S100 staining was positive in all three cases. Table 3 demonstrates the important demographic, radiological and histological features of schwannoma, neurofibroma and MPNST.

## Conclusion

Subperiosteal schwannoma is a very rare entity and diffi-



**Table 3.** Typical demographic, radiological and histological features of peripheral nerve sheath tumors

Feature	Schwannoma	Neurofibroma	Malignant peripheral nerve sheath Tumor
<b>Demographic<sup>[32]</sup></b>			
Prevalence	5% of all benign soft tissue tumors	5% of all benign soft tissue tumors	6% of all soft tissue sarcoma
Multiplicity and association with neurofibromatosis type 1 (NF 1) Site	Usually solitary, 5%–18% multiple lesions have NF 1	Typically solitary; multiple lesions in NF1	Solitary and 50% of lesions appear in patients with NF1
Malignant change	Mostly in head and neck and upper extremity	Usually head and neck region and lower extremity	Major nerve trunk (commonly in proximal extremities)
	Extremely rare	Extremely rare except in NF1	Not applicable
<b>Radiographic</b>			
RelationMRI <sup>[29]</sup> to nerve	Eccentric	Central	Central
Target sign	Present	Present (more often)	Absent
Split fat sign	Present	Present	Absent
Intra-tumoral cyst	Common	Rare	Occasional
Bone destruction	May be present	May be present	Usual
Perilesional edema	Absent	Absent	Present
Post contrast enhancement	Peripheral and	Central	Peripheral and heterogenous
Echogenicity USG <sup>[26]</sup>	Heterogenous		
	Hypochoic (more often)	Hypochoic	Hypo to mix echogenicity
Internal homogeneity	Homogeneous (more often)	Homogeneous and Heterogeneous	Homogeneous and Heterogeneous
Continuity with involved nerve	Present	Present	Present
<b>Margins<sup>[32]</sup></b>			
	Well circumscribed	Well circumscribed	More often well circumscribed than irregular
<b>Pathological and Immunophenotypic</b>			
NuclearFeatures <sup>[31]</sup> Size	++	+	++/+++
Nuclear hyperchromasia	++	+	+++
Capsule	+++	-	-
Mitotic activity	-/+	-/+	+++
Necrosis	-/+	-	+++
“Shredded carrot” type Collagen	-/+	+++	-/+
<b>IHC marker</b>			
S100	+++	++/+++	+ / ++
Collagen type IV	+++	++/+++	+ / ++

cult to diagnose due to non-specific symptoms. In some cases, due to the absence of a defined mass and a normal radiograph, diagnosis is difficult. An inexpensive and readily available USG can reliably demonstrate PNST. Early diagnosis with ultrasonography can spare the patient a prolonged and ineffective course of NSAID. Though PNST is rare, it must be considered as a differential diagnosis for surface lesion of the bone.

#### Disclosures

**Ethics Committee Approval:** Institutional Ethics Committee, All India Institute of Medical Sciences, Bhubaneswar. (Regd No. ECR/534/Inst/OD/2014/RR-17) Reference No. of approval: T/IM-NF/Ortho/19/22. Date of approval: 17/08/2019.

**Peer-review:** Externally peer-reviewed.

**Conflict of Interest:** None declared.

**Authorship Contributions:** Concept – B.P.; Design – B.P., S.K.P.; Supervision – B.P., S.K.P.; Materials – S.D., S.B.; Data collection &/or processing – S.B., S.D., G.A., S.K.D.; Analysis and/or interpretation – S.B., S.D.; Literature search – S.D., S.B.; Writing – S.D., S.B.; Critical review – G.A., S.K.D., B.P., S.K.P.

#### References

- Weiss SW, Goldblum JR, Enzinger FM. Benign tumours of the peripheral nerves. In: Weiss S, Goldblum JR, eds. Enzinger and Weiss's soft tissue tumours. Fourth ed. St. Louis: Mosb 2001;1111–208.
- Kim DH, Murovich JA, Tiel RL, Moes G, Kline DG. A series of 397 peripheral neural sheath tumors: 30-year experience at Louisiana State University Health Sciences Center. J Neurosurg 2005;102:246–55. [\[CrossRef\]](#)
- Corfas G, Velardez MO, Ko CP, Ratner N, Peles E. Mechanisms and roles of axon–schwann cell interactions. Neurosci

- 2004;24:9250–60. [\[CrossRef\]](#)
4. Knight DMA, Birch R, Pringle J. Benign solitary schwannomas, review of 234 cases. *J Bone Joint Surg [Br]* 2007;89–B:382–7.
  5. Baehring JM, Betensky RA, Batchelor TT. Malignant peripheral nerve sheath tumor: the clinical spectrum and outcome of treatment. *Neurology* 2003;61:696–8. [\[CrossRef\]](#)
  6. Woodruff JM, Selig AM, Crowley K, Allen PW. Schwannoma (neurilemoma) with malignant transformation: a rare distinctive peripheral nerve tumour. *Am J Surg Pathol* 1994;18:882–95.
  7. Ogose A, Hotta T, Morita T, Otsuka H, Hirata Y. Multiple schwannomas in the peripheral nerves. *J Bone Joint Surg [Br]* 1998;80–B:657–61. [\[CrossRef\]](#)
  8. Ida CM, Scheithauer BW, Yapicier Ö, Carney JA, Wenger DE, Inwards CY et al. Primary schwannoma of the bone: A clinicopathologic and radiologic study of 17 cases. *Am J Surg Pathol* 2011;35:989–97. [\[CrossRef\]](#)
  9. Hilton DA and Hanemann CO. Schwannomas and their pathogenesis. *Brain Pathol* 2014;24:205–20. [\[CrossRef\]](#)
  10. Salla JT, Johann ACBR, Garcia BG, Aguiar MCF, Mesquita RA. Retrospective analyses of oral peripheral nerves sheath tumors in Brazilians. *Braz Oral Res* 2009;23:43–8. [\[CrossRef\]](#)
  11. Santos PPA, Freitas VS, Pinto LP, Freitas RA, Souza LB. Clinicopathologic analysis of 7 cases of oral schwannoma and review of the literature. *Ann Diagn Pathol* 2010;14:235–9. [\[CrossRef\]](#)
  12. Igai H, Kamiyoshihara M, Kawatani N, Ibe T, Shimizu K. Sternal intraosseous schwannoma mimicking breast cancer metastasis. *J Cardiothorac Surg* 2014;9:116. [\[CrossRef\]](#)
  13. Samter TG, Vellios F, Shafer WG. Neurilemoma of bone. Report of 3 cases with a review of the literature. *Radiology* 1960;75:215–22. [\[CrossRef\]](#)
  14. Kehoe NJ, Reid RP, Semple JC. Solitary benign peripheral-nerve tumours. Review of 32 years' experience. *J Bone Joint Surg Br* 1995;77:497–500. [\[CrossRef\]](#)
  15. Paksoy Y, Sahin M, Avunduk MC, Aksoy F, Odev K. Solitary juxtacortical neurofibroma of the humerus. *Skeletal Radiol* 2002;31:112–15. [\[CrossRef\]](#)
  16. Verma RR, Khan MT, Davies AM, Mangham DC, Grimer RJ. subperiosteal schwannomas of the femur. *Skeletal Radiol* 2002;31:422–25. [\[CrossRef\]](#)
  17. Lakhota D, Jeph S and Sharma S. Subperiosteal schwannoma of pelvis- A rare case and review of literature. *J Clin Diagn Res* 2016;10:RD01–RD03. [\[CrossRef\]](#)
  18. Albert P, Patel J, Badawy K, Weissinger W, et al. Peripheral nerve schwannoma: A review of varying clinical presentations and imaging findings. *J Foot Ankle Surg* 2017;56:1–6. [\[CrossRef\]](#)
  19. Kransdorf MJ. Benign soft-tissue tumors in a large referral population: distribution of specific diagnoses by age, sex, and location. *AJR* 1995;164:395–402. [\[CrossRef\]](#)
  20. Das Gupta TK, Brasfield RD, Strong EW, Hajdu SI. Benign solitary schwannomas (neurilemmomas). *Cancer* 1969;24:355–66.
  21. Lhedan FA. Schwannoma of the femur: A rare case report. *J Bone Oncol* 2017;8:1–3. [\[CrossRef\]](#)
  22. Singh V, Grimer R. Subperiosteal schwannoma of the ulna. *The IJOS* 2005;3. [\[CrossRef\]](#)
  23. Kenan S, Abdelwahab IF, Klein MJ, Hermann G, Lewis MM. Lesions of juxtacortical origin (surface lesions of bone). *Skeletal Radiol* 1994;22:337–357. [\[CrossRef\]](#)
  24. Seeger LL, Lawrence Y, Eckardt JJ. Surface lesions of bone. *Radiology* 1998;206:17–33. [\[CrossRef\]](#)
  25. Andrew SM, Freemont AJ. Juxtacortical malignant schwannoma with heterologous elements. *Histopathology* 1993;23:280–2. [\[CrossRef\]](#)
  26. Reynolds DL Jr, Jacobson JA, Inampudi P, Jamadar DA, Ebrahim FS, Hayes CW. Sonographic characteristics of peripheral nerve sheath tumors. *AJR Am J Roentgenol* 2004;182:741–4.
  27. Tsai W, Chiou H, Chou Y, Wang H, Chiou S and Chang C. Differentiation between schwannomas and neurofibromas in the extremities and superficial body. *J Ultrasound Med* 2008;27:161–6. [\[CrossRef\]](#)
  28. Chee DW, Peh WC, Shek TW. Pictorial essay: Imaging of peripheral nerve sheath tumors. *Can Assoc Radiol J* 2011;62:176–82.
  29. Kakkar C, Shetty CM, Koteswara P, Bajpai S. Telltale signs of peripheral neurogenic tumors on magnetic resonance imaging. *Indian J Radiol Imaging* 2015;25:453–8. [\[CrossRef\]](#)
  30. Zaidman CM, Seelig MJ, Baker JC, Mackinnon SE, Pestronk A. detection of peripheral nerve pathology: Comparison of ultrasound and MRI. *Neurology* 2013;80:1634–40. [\[CrossRef\]](#)
  31. Rodriguez FJ, Folpe AL, Giannini C, Perry A. Pathology of peripheral nerve sheath tumors: Diagnostic overview and update on selected diagnostic problems. *Acta Neuropathol* 2012;123:295–319. [\[CrossRef\]](#)