



Case Report

Posterior Mediastinal Hemangioma: A Case Report and Review of Literature

 Hakan Keskin,  Sirin Akdeniz

Department of Thoracic Surgery, Akdeniz University Faculty of Medicine, Antalya, Turkey

Abstract

Hemangiomas, which are benign vascular tumors occurring throughout the body and most commonly in the liver, are extremely rare in the posterior mediastinum. There are fewer than 25 cases reported in the English literature. Most patients are asymptomatic, whereas some may present with symptoms related to compression of the surrounding tissues. Generally, definitive diagnosis requires histopathological examination following surgery. We present a case of a 50-year-old woman with a gradual onset dyspnea for 12 years and right-sided pleural effusion. Drainage of the effusion revealed a posterior mediastinal mass in the chest computed tomography. The mass was completely removed with thoracotomy, though it required careful hemostasis. Histopathological examination confirmed a diagnosis of hemangioma. Thoracotomy or video-assisted thoracoscopic surgery may be preferred depending on the surgeon's experience and the risk of massive bleeding. Ideally, the surgical procedure should aim the total excision of the lesion; however, outcomes of subtotal excision are also satisfactory.

Keywords: Capillary, hemangioma, mediastinum, mediastinal diseases

Hemangiomas are proliferative lesions that are characterized by increased proliferation of vascular endothelial cells and are usually identified after birth. Mediastinal hemangioma is a rare entity that was first reported in 1914 by Shannon.^[1] They comprise about 0.5% of all mediastinal tumors.^[2] Preoperative diagnosis is difficult because, although there are characteristic findings in radiologic imaging studies, they are present in less than 20% of the cases.^[3] Hemangiomas are predominantly seen in the anterior mediastinum. Fewer than 25 cases of posterior mediastinal hemangioma (PMH) have been reported in the English literature, none of which are from Turkey.

Case Report

A 50-year-old woman was referred to the thoracic surgery outpatient clinic with a complaint of intermittent shortness

of breath that was present for at least 12 years and gradually increasing for about 1 year. The patient also had posterior chest pain that started 1 year ago and had been increasing in intensity since. The patient had been evaluated for dyspnea in another medical facility 7 months ago and a pleural effusion was detected on chest x-ray. Diagnostic thoracentesis was performed at the time, but cytology did not yield pathologic results. In our evaluation, physical examination was unremarkable except diminished breath sounds over the right hemithorax. Complete blood count and blood chemistry were within normal limits. In the chest x-ray, there was a right-sided pleural effusion filling two-thirds of the hemithorax. The patient was admitted for further evaluation and symptomatic relief. The pleural effusion was drained with a tube thoracostomy and samples of pleural fluid were obtained for repeat cytology and cultures. The results indicated exudative pleural effusion but

Address for correspondence: Sirin Akdeniz, MD. Akdeniz Universitesi Tip Fakultesi, Gogus Cerrahisi Anabilim Dalı, Antalya, Turkey

Phone: +90 505 270 80 24 **E-mail:** sirinakdeniz@hotmail.com

Submitted Date: December 05, 2017 **Accepted Date:** December 18, 2017 **Available Online Date:** October 11, 2018

©Copyright 2018 by Eurasian Journal of Medicine and Oncology - Available online at www.ejmo.org



failed to point to a malignant or infectious etiology. Following re-expansion of the lung, computed tomography (CT) of the chest was done, which revealed a mass in the paravertebral space with a size of 3x3 centimeters. The patient was scheduled for thoracotomy and total excision of the mass with a preoperative diagnosis of neurogenic tumor (neurofibroma) (Fig. 1). During the operation, the mass was completely excised, but unusually high amount of bleeding from surrounding tissues required careful hemostasis with propylene monofilament sutures. On gross examination, the outer surface was covered with pleura, cut surface was off-white in color with irregular foci of hemorrhage. Tissue samples were stained with immunohistochemistry for CD31, CD34, S-100 and pancytokeratin, which confirmed a diagnosis of hemangioma (Fig. 2). There were no complications postoperatively during the hospital stay or in the first-year follow-up.

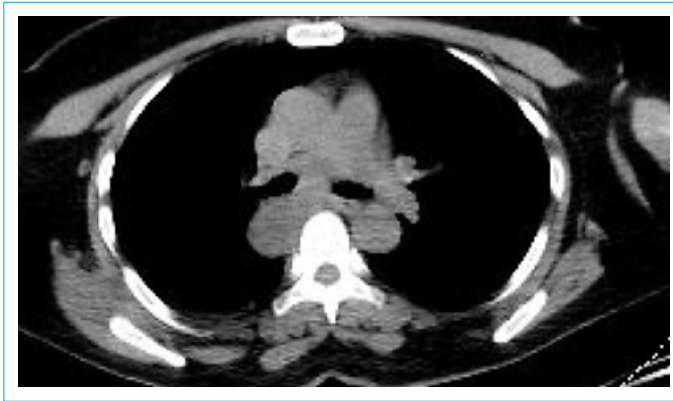


Figure 1. Axial image of computed tomography of the chest, mediastinal window, showing a mass in the right paravertebral space.

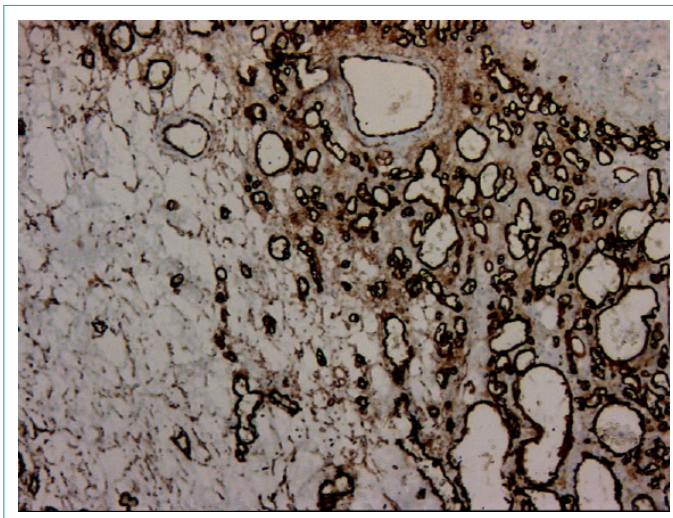


Figure 2. Congested vascular spaces underneath multiple layers of squamous epithelial cells, hematoxylin eosin staining and immunohistochemical staining for CD34.

Discussion

Hemangiomas are benign tumors that can arise anywhere in the body. Mediastinal hemangiomas are predominantly seen in the anterior mediastinum. In the English literature, fewer than 25 cases of PMH have been reported (Table 1). PMH can infiltrate neighboring tissues microscopically, however, it has limited potential for aggressive biological behavior.

75% of mediastinal hemangiomas are encountered before the age of 35, while 75% of PMH are encountered after the age of 35. Typically seen in adults, pediatric cases of the latter have also been reported. While there seems to be no gender preference in mediastinal hemangiomas, reported cases of PMH are usually female patients.

PMH cases are usually asymptomatic and lesions are identified incidentally on imaging studies. In symptomatic cases, symptoms vary according to tumor size and location and may include non-specific chest pain, cough, and dysphagia. In our case, the patient presented with recurrent pleural effusion and posterior chest pain.

Mediastinal hemangiomas are extremely difficult to diagnose preoperatively. Yamazaki et al.^[4] reported a preoperative definitive diagnosis in only 2 out of 61 cases of mediastinal hemangiomas in Japan. There are no reported cases of posterior mediastinal hemangiomas in the literature with a preoperative definitive diagnosis. In the chest CT, the lesion appears as a homogenous mass with lobulated margins, which is similar to a neurofibroma. Hemangiomas are identifiable by phleboliths, which look like circular calcifications within a mass, seen in the bone window of a chest CT. However, phleboliths are seen in less than 20% of the cases.^[2] There are reports that demonstrate the efficacy of magnetic resonance imaging (MRI) in the diagnosis of mediastinal tumors.^[5] Significantly high intensity on fat-suppressed T2-weighted images may be characteristic in MRI.^[6] Our patient was operated with a preliminary diagnosis of neurofibroma, which is the most common tumor in the posterior mediastinum.

As chest CT and MRI are inadequate in the definitive diagnosis of PMH, histopathological confirmation is required. Percutaneous needle biopsies are not recommended due to the risk of bleeding. Though video-assisted thoracoscopic surgery (VATS) is gaining more and more widespread use, we believe surgical treatment with thoracotomy is safer and more appropriate for a VATS-inexperienced surgeon, because the risk of massive bleeding can be managed under controlled conditions with thoracotomy. Total excision is the recommended procedure, especially for cases without infiltration to neighboring structures, however, subtotal resections are acceptable in infiltrative tumors, since symptoms

Table 1. Characteristics of posterior mediastinal hemangioma

Author	Age	Sex	Symptom	Tumor Size (cm)	Radiologic Diagnosis	Treatment
Ridene et al. ^[2]	58 y	F	Incidental finding	5	Neurogenic tumor	Thoracotomy complete excision
Ridene et al. ^[2]	66 y	M	Paresthesia of upper extremity	6	N/A	Thoracotomy complete excision
Ridene et al. ^[2]	16 y	N/A	Asymptomatic	5	N/A	Video assisted thoracic surgery, complete excision
Zeyainan et al. ^[3]	65 y	F	Productive cough	5	Neurogenic tumor	Thoracotomy, complete excision
Yoshino et al. ^[6]	54 y	F	Asymptomatic	2.7	Suspicious to neurogenic tumor	Thoracoscopic thoracotomy
Hammoumi et al. ^[7]	63	M	Dysphagia	6	Haematic liquid	Thoracotomy, complete excision
Maeda et al. ^[8]	67 y	M	Asymptomatic	N/A	Neurogenic tumor	Thoracotomy, complete excision
Yun et al. ^[9]	58 y	F	Back pain	6	N/A	Thoracotomy, complete excision
Moran et al. ^[10]	1 m	F	Rectal bleeding + facial telangiectasia	N/A	Hemangioma	Autopsy finding
Moran et al. ^[10]	48 y	F	Cough	3	N/A	Thoracotomy complete excision
Moran et al. ^[10]	37 y	M	Asymptomatic	9	N/A	Thoracotomy complete excision
Moran et al. ^[10]	35 y	F	Neck pain	7	N/A	Thoracotomy complete excision
Herman et al. ^[11]	7 m	F	Work up for coronary heart disease	N/A	Neuroblastoma	Only biopsy
Herman et al. ^[11]	8 w	N/A	Cyanosis, apnea	N/A	N/A	Thoracotomy, partial resection, alfa interferon, short course steroid
Taori et al. ^[12]	25 y	M	Back pain	9	N/A	Thoracotomy, complete excision
Sabharwal et al. ^[13]	4 m	F	Work up for tetralogy of Fallot	2	Suspicious to neuroblastoma	Thoracotomy, complete excision
Sabharwal et al. ^[13]	6 m	F	Work up for congestive heart failure	Multiple	Suspicious to neuroblastoma	Thoracotomy complete excision
Ampollini et al. ^[14]	71	F	Asymptomatic	5	N/A	Video assisted thoracic surgery
Karamalou et al. ^[15]	57 y	F	Epigastric pain dyspnea	12.8	N/A	Thoracotomy, complete excision
Kubokura et al. ^[16]	58 y	M	Dyspnea, dysphagia, back pain	8	N/A	Thoracotomy, cystectomy
Seki et al. ^[17]	69 y	F	Asymptomatic	3.2	Neurogenic tumor	video-assisted thoracic surgery
Das et al. ^[18]	56 y	F	Chest pain	6	N/A	Thoracotomy, complete excision

F: Female; M: Male; m: Month; w: Week; y: Year; N/A: Data not available.

arise due to the mass effect of the tumor, and subside when the mass effect diminishes. Also, there are no reports of malignant transformation of mediastinal hemangiomas.^[7] However, patients must be closely followed up, because local recurrence, though rare, is possible.^[7] For patients with local recurrence, one treatment option is vascular embolization, but it should be noted that there is a risk of spinal infarct for

PMH involving the lower thoracic vertebrae or extending into the spinal canal through intervertebral foramina.^[8] In such cases, reoperation is recommended. The effect of radiotherapy on these cases is not well known.^[9]

In conclusion, PMH is an extremely rare benign tumor, although it may show local invasion. It is hard to diagnose

with a chest CT or MRI; thus the diagnosis is usually made during surgery. For locally infiltrated lesions, subtotal resection of the tumor is acceptable in managing the risk of massive intraoperative bleeding.

Disclosures

Informed consent: Written informed consent was obtained from the patient for the publication of the case report and the accompanying images.

Peer-review: Externally peer-reviewed.

Conflict of Interest: None declared.

Authorship Contributions: Concept – H.K.; Design – H.K.; Supervision – H.K.; Materials – H.K.; Data collection &/or processing – H.K.; Analysis and/or interpretation – H.K., S.A.; Literature search – H.K.; Writing – H.K., S.A.; Critical review – H.K., S.A.

References

1. Shanon T. Histologically nonmalignant hemangioma with numerous metastasis. *J Pathol* 1914;19:139–54.
2. Ridene I, Abassi A, Baccouche I, et al. Posterior mediastinal hemangioma mimicking neurogenic tumor: report of two cases. *Eur J Radiol Extra* 2010;75:e55–8.
3. Zeyaian B, Soleimani N, Geramizadeh B. Posterior mediastinal capillary hemangioma misdiagnosed as neurofibromas: a rare case report and review of the literature. *Rare Tumors* 2015;7:5639.
4. Yamazaki A, Miyamoto H, Saito Y, Matsuzawa H, Sakao Y, Anami Y. Cavernous hemangioma of the anterior mediastinum: case report and 50-year review of Japanese cases. *Jpn J Thorac Cardiovasc Surg* 2006;54:221–4.
5. Özgökçe M, Alper F, Aydın Y, Oğul H, Akgün M. Using cine magnetic resonance imaging to evaluate the degree of invasion in mediastinal masses. *Turk Gogus Kalp Damar* 2015;23:309–15.
6. Yoshino N, Okada D, Ujiiie H, Akiyama H, Nishimura Y, Koizumi K, et al. Venous hemangioma of the posterior mediastinum. *Ann Thorac Cardiovasc Surg* 2012;18:247–50.
7. Hammoumi MM, Sinaa M, Arsalane A, Oueriachi FE, Kabiri el H. Mediastinal cystic haemangiomas: a two cases report and review of the literature. *Heart Lung Circ* 2014;23:e118–21.
8. Maeda S, Takahashi S, Koike K, Sato M. Preferred surgical approach for dumbbell-shaped tumors in the posterior mediastinum. *Ann Thorac Cardiovasc Surg* 2011;17:394–6.
9. Yun T, Suzuki H, Tagawa T, Iwata T, Mizobuchi T, Yoshida S, et al. Cavernous hemangioma of the posterior mediastinum with bony invasion. *Gen Thorac Cardiovasc Surg* 2016;64:43–6.
10. Moran CA, Suster S. Mediastinal hemangiomas: a study of 18 cases with emphasis on the spectrum of morphological features. *Hum Pathol* 1995;26:416–21.
11. Herman TE, McAlister WH, Dehner LP. Posterior mediastinal capillary hemangioma with extradural extension resembling neuroblastoma. *Pediatr Radiol* 1999;29:517–9.
12. Taori KB, Mitra KR, Mohite AR, Bhawatkar AJ, Siddique AQ. A case report and review of literature: posterior mediastinal haemangioma. *Indian J Radiol Imaging* 2002;12:83–5.
13. Sabharwal GK, Strouse PJ. Posterior mediastinal hemangioma. *Pediatr Radiol* 2005;35:1263–6.
14. Ampollini L, Carbognani P, Cattelani L, Bilancia R, Rusca M. Cavernous hemangioma of the posterior mediastinum. *Ann Thorac Surg* 2010;90:e96.
15. Karamlou T, Kinder K, Tieu B, Sauer D, Schipper P. Mediastinal hemangioma arising in setting of partial anomalous pulmonary venous drainage to azygous vein in a 57-year-old woman. *Ann Vasc Surg* 2011;25:559.e13–7.
16. Kubokura H, Okamoto J, Hoshina H, Ishii H, Koizumi K, Shimizu K. Mediastinal cystic hemangioma presenting as bilateral bloody pleural effusion: a case report. *J Nippon Med Sch* 2012;79:381–4.
17. Seki Y, Yasuda A, Gotou M, Sugiyama T, Yamada K. Posterior mediastinal hemangioma with extramedullary haematopoiesis. *Kyobu Geka* 2012;65:380–3.
18. Das A, Das SK, Basuthakur S, Das S. Hemangioma in the posterior mediastinum. *Lung India* 2014;31:186–8.