

Research Article

Lenvatinib With or Without Immune Checkpoint Inhibitors in Subsets of Advanced Hepatocellular Carcinoma

 Yu-Xian Teng,^{1,*}  Ping-Ping Guo,^{2,*}  Ke-Zhang Qin,^{1,*}  Kang Chen,¹  George Papatheodoridis,¹
 Bang-De Xiang,¹  Liang Ma,¹  Jian-Hong Zhong¹

¹Department of Hepatobiliary Surgery, Guangxi Liver Cancer Diagnosis and Treatment Engineering and Technology Research Center, Guangxi Medical University Cancer Hospital, Nanning, China

²Department of Ultrasound, Guangxi Medical University Cancer Hospital, Nanning, China

³Department of Gastroenterology, Medical School of National and Kapodistrian University of Athens, General Hospital of Athens "Laiko", Athens, Greece

*Yu-Xian Teng, Ping-Ping Guo, and Ke-Zhang Qin contributed equally to this work.

Abstract

Objectives: Targeted agents combined with immune checkpoint inhibitors (ICIs) for advanced hepatocellular carcinoma (HCC) may improve survival for some patients. This study aims to identify the patients who are most likely to benefit from combination therapy.

Methods: The study included 45 patients receiving lenvatinib while other 65 patients receiving lenvatinib plus ICIs between January 2019 and August 2020. Clinical and laboratory data were evaluated and compared.

Results: The median follow-up was 20.5 months in the lenvatinib and 18.0 months in the combination group. The corresponding median overall survival was 9.3 and 13.0 months ($p=0.004$), respectively. Subgroup analyses found that lenvatinib plus ICIs was associated with better overall survival in patients younger than 60 years, males, without MAFLD as well as with BMI <23 kg/m², cirrhosis, HBV infection, total tumor volume ≥ 982 cm³, tumor burden score of ≥ 10.4 or α -fetoprotein ≥ 200 ng/ml.

Conclusion: Lenvatinib plus ICIs therapy seems to be more effective in advanced HCC patients with viral etiology, low BMI, or high tumor load.

Keywords: Hepatocellular carcinoma, Immune checkpoint inhibitors, Lenvatinib, Overall survival

Cite This Article: Teng YX, Guo PP, Qin KZ, Chen K, Papatheodoridis G, Xiang BD, Ma L, Zhong JH. Lenvatinib With or Without Immune Checkpoint Inhibitors in Subsets of Advanced Hepatocellular Carcinoma. EJMO 2022;6(1):25–29.

The efficacy of targeted agents combined with immune checkpoint inhibitors (ICIs) has been shown to be better than that of targeted agents alone in patients with advanced hepatocellular carcinoma (HCC), but not all patients benefit from combination therapy.^[1–5] Identifying the patients who are most likely to benefit from each therapy is critical for improving their overall management. The subgroup analyses of IMbrave150,^[6] CheckMate 459^[7] and KEYNOTE-240^[8] suggested that the effects

of targeted immunotherapy in advanced HCC depend on liver disease aetiology.^[9] Namely, patients with non-viral HCC appeared to have no significant benefit from ICIs. Two other cohorts also supported the ineffectiveness of ICIs in non-alcoholic fatty liver disease related HCC.^[9] In fact, patients with non-alcoholic fatty liver disease related HCC have significant different survival after hepatic resection or lenvatinib monotherapy than those with other etiology-related HCC.^[10–12]

Address for correspondence: Jian-Hong Zhong; Liang Ma, MD. Guangxi Medical University Cancer Hospital, He Di Rd 71, Nanning 530021, China

Phone: +86 771 5310253 **E-mail:** zhongjianhong@gxmu.edu.cn; maliangxyd@163.com

Submitted Date: February 10, 2022 **Accepted Date:** March 7, 2022 **Available Online Date:** March 10, 2022

©Copyright 2022 by Eurasian Journal of Medicine and Oncology - Available online at www.ejmo.org

OPEN ACCESS This work is licensed under a Creative Commons Attribution-NonCommercial 4.0 International License.



Nowadays, many basic researches have investigated the biomarkers of response and sensitivity to ICIs therapy.^[13,14] However, these studies use very sophisticated methods. Histopathologic biomarker to predict the response and sensitivity to ICIs therapy would be a therapeutic target for enhancing the efficacy of ICIs therapy. Cytokeratin 19 (CK19) and Ki-67 are two items that routinely reported in histopathology after HCC resection. Some studies found CK19 and Ki-67 are associated with immune microenvironment and molecular classification in HCC.^[15,16] However, no study investigated the role of CK19 and Ki-67 as histopathologic biomarker to predict the response and sensitivity to ICIs therapy.

Whether additional factors affect the efficacy of ICIs in patients with HCC has not been clarified. This brief report explored the factors influencing the efficacy of lenvatinib with or without ICIs in advanced HCC based on data from real-world clinical practice. Moreover, the role of CK19 and Ki-67 as histopathologic biomarker to predict the response to ICIs therapy was also investigated.

Methods

The cohorts of this study were previously described.^[17] However, subgroup analysis to reveal the subsets with the best benefit from combination therapy was not performed. In the combination cohort, ICIs included pembrolizumab (n=5), camrelizumab (n=31), sintilimab (n=21), toripalimab (n=7) and tislelizumab (n=1). The definition of metabolic dysfunction-associated fatty liver disease (MAFLD) was based on presence of steatosis in >5% of hepatocytes, in

addition to body mass index (BMI) ≥ 23 kg/m², type 2 diabetes mellitus or metabolic dysregulation.^[18] The independent effects of baseline factors including age, gender, BMI, steatosis, MAFLD, cirrhosis, hepatitis B virus (HBV) infection, total tumor volume, tumor burden score and α -fetoprotein on the efficacy of the two groups (lenvatinib alone vs lenvatinib+ICI) were assessed by multivariable analyses. Objective response was not reported in this brief report because of the small sample size in some subgroups.

The definition of tumor burden score was described previously.^[19] It is defined using distance from the origin on a Cartesian plane incorporating maximum tumor size (x-axis) and number of lesions (y-axis).^[19] The total tumor volume is calculated by the addition of the volume of each individual tumor.^[20]

All included patients had Child-Pugh class A or B liver function, an Eastern Cooperative Oncology Group performance status of 0 or 1 at the time of lenvatinib initiation. As histology data was missing in some patients, liver cirrhosis could not be graded. The median duration of lenvatinib therapy was 10.2 (1.2-23.7) months in the combination group and 8.2 (1.1-23.7) months in the lenvatinib monotherapy group, respectively. Patients in the combination group were treated with a total of 508 cycles of ICIs (median 7, range 1-21).

Results

Patients in the lenvatinib group were significantly older, while all other baseline characteristics were comparable between the two groups (Table 1). The follow-up was

Table 1. Characteristics of the Study Cohort.

Variable	Lenvatinib (n=45)	Lenvatinib + ICIs (n=65)	p
Median age, y	56	51	0.020
Male gender, n (%)	42 (93.3)	55 (84.6)	0.233
Mean BMI (kg/m ²)	22.8	22.8	0.997
BMI ≥ 23 kg/m ² , n (%)	17 (37.8)	28 (43.1)	0.694
Type 2 diabetes, n (%)	4 (8.9)	7 (10.8)	1.000
Hypertension, n (%)	11 (24.4)	7 (10.8)	0.69
Triglycerides (>1.70 mmol/L), n (%)	5 (11.1)	5 (7.7)	0.738
High-density lipoprotein (<1.0 mmol/L for man and <1.3 mmol/L for women, n (%))	14 (31.1)	25 (38.5)	0.544
>5% steatosis, n (%)	21 (46.7)	19 (29.2)	0.072
MAFLD, n (%)	14 (31.1)	14 (21.5)	0.274
Liver cirrhosis, n (%)	32 (71.1)	52 (80.0)	0.362
HBV infection*, n (%)	20 (44.4)	40 (61.5)	0.084
Anti-HCV, positive, n (%)	2 (4.4)	4 (6.2)	1.000
Mean total tumor volume, cm ³	984.4	982.5	0.993
Mean tumor burden score,	10.4	10.7	0.809
α -fetoprotein ≥ 200 ng/ml, n (%)	25 (55.6)	41 (63.1)	0.553

*Not including patients with other etiology; BMI, body mass index; MAFLD, metabolic dysfunction-associated fatty liver disease.

updated on 15 October 2021. The median follow-up was 20.5 months in the lenvatinib and 18.0 months in the combination group. At the time of analysis, 35 (77.8%) and 33 (50.8%) deaths occurred in the lenvatinib and the combination group, respectively. Patients in the combination group had significantly better overall survival than those in the lenvatinib group (hazard ratio=0.51; 95% confidence interval, 0.31-0.84; Fig. 1a); median overall survival was 13.0 and 9.3 months, respectively.

And then, subgroup analysis based on patients with and without MAFLD was performed. Each group had 14 patients with MAFLD. The two groups had similar OS (hazard ratio=0.54; 95% confidence interval, 0.22-1.33; Fig. 1b). However, among those without MAFLD, patients with combination therapy had statistically higher OS than those with lenvatinib monotherapy (hazard ratio=0.51; 95% confidence interval, 0.28-0.93; Fig. 1c).

Subgroup analyses based on other variables were also performed. Lenvatinib plus ICIs compared to lenvatinib was associated with better overall survival in patients younger than 60 years, males as well as with BMI <23 kg/m², cirrhosis, HBV infection, total tumor volume \geq 982 cm³, tumor burden score of \geq 10.4 or α -fetoprotein \geq 200 ng/ml (Fig. 2).

Twenty-two patients have been underwent hepatic resection before lenvatinib plus ICIs therapy for recurrent HCC.^[17] All these patients were with postoperative histopathological analysis for CK19 and Ki-67. Seven (31.8%) of them were positive with CK19 expression. The median expression of Ki-67 was 40% (range 5% to 80%). Patients without CK19 expression have higher overall (hazard ratio=0.42; 95% confidence interval, 0.09-1.86; Fig. 3a) and progression-free survival trend (hazard ratio=0.27; 95% confidence interval, 0.07-1.01; Fig. 3b). However, patients with Ki-67 low expression (n=11) had very similar overall (hazard ratio=0.89; 95%

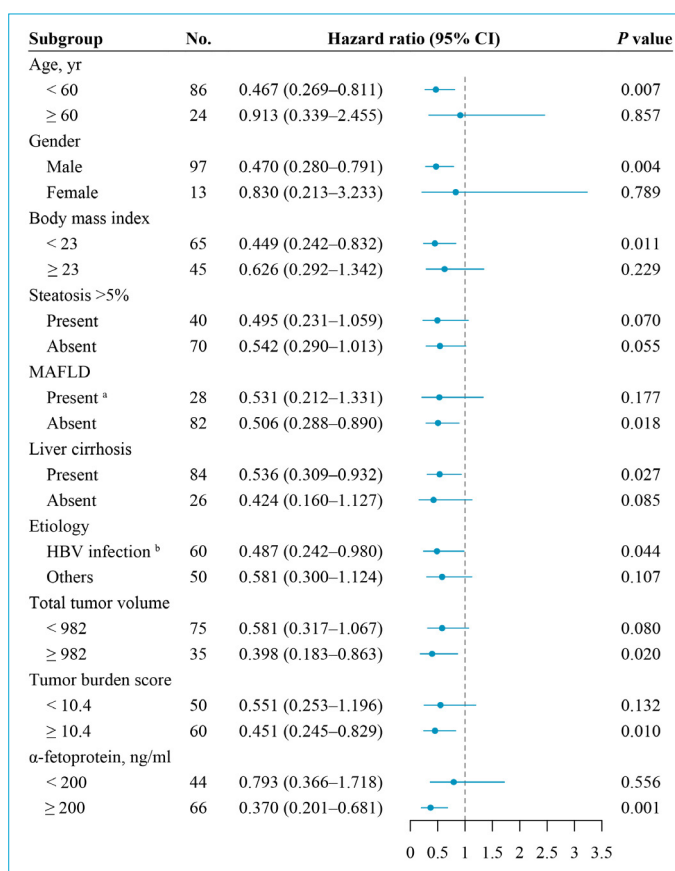


Figure 2. Subgroup analyses of total population.

^aIncluding patients with hepatitis B virus infection.

^bNot including patients with other etiology.

CI: confidence interval; HR: hazard ratio; ICIs: immune checkpoint inhibitors; Len: lenvatinib; MAFLD: metabolic dysfunction-associated fatty liver disease.

confidence interval, 0.23-3.39; Fig. 3c) and progression-free survival (hazard ratio=0.49; 95% confidence interval, 0.16-1.49; Fig. 3d) with those with high expression.

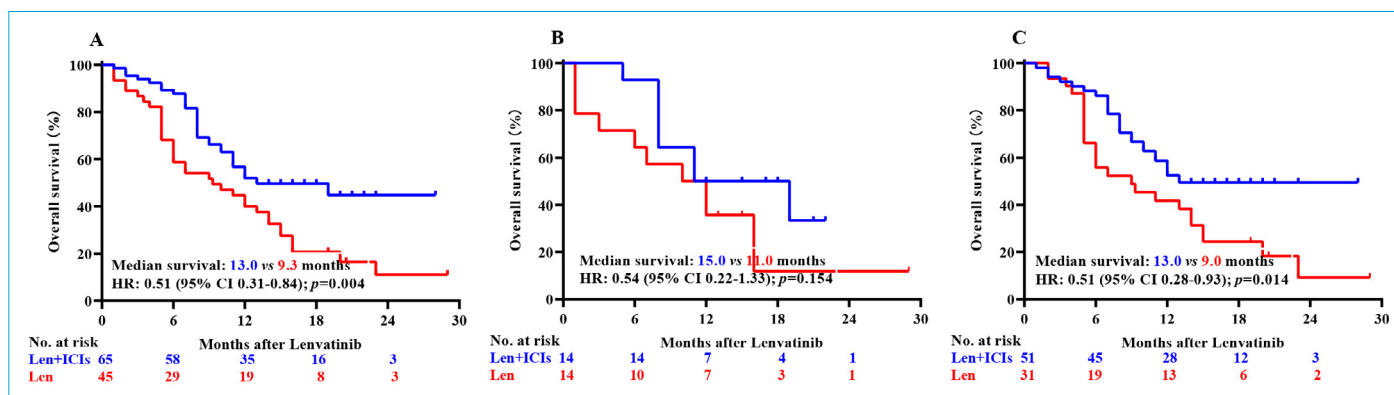


Figure 1. Overall survival analyses for patients treated with lenvatinib monotherapy vs lenvatinib plus immune checkpoint inhibitors. (a) Kaplan–Meier curves for total population; (b) Kaplan–Meier curves for patients with MAFLD; (c) Kaplan–Meier curves for patients without MAFLD. CI, confidence interval; HR, hazard ratio; ICIs, immune checkpoint inhibitors; Len, lenvatinib.

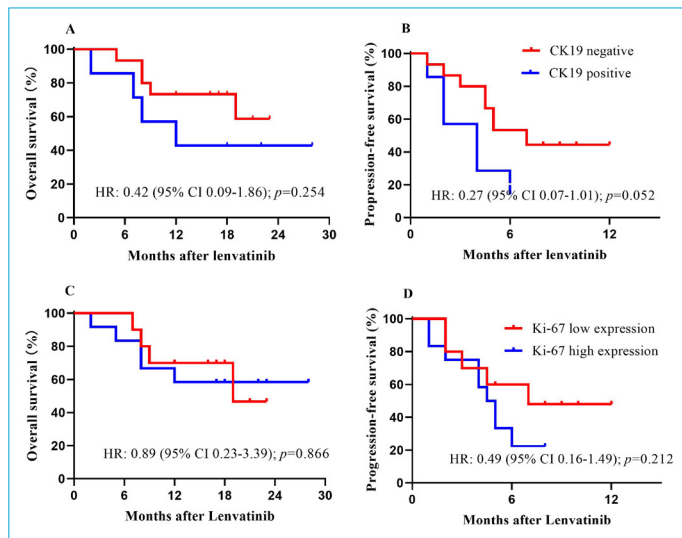


Figure 3. Survival analyses for patients treated with lenvatinib plus immune checkpoint inhibitors for recurrent hepatocellular carcinoma. (a) Overall survival for CK19 positive (n=7) or negative (n=15); (b) Progression-free survival for CK19 positive (n=7) or negative (n=15); (c) Overall survival for Ki-67 low expression (n=11) or high expression (n=11); (d) Progression-free survival for Ki-67 low expression (n=11) or high expression (n=11). CI, confidence interval; HR, hazard ratio.

Discussion

This study has several interesting findings. First, the conclusions of previous reports^[9] that NAFLD-related HCC is less responsive to immunotherapy are further supported by our results coming from an HBV endemic region, as patients with HBV infection and those without MAFLD were found to benefit most from the combination of lenvatinib with ICIs. Second, lenvatinib plus ICIs appeared to improve the overall survival in patients with HCC and low BMI, which is in contrast with reports for better efficacy of ICI therapy in patients with advanced non-small cell lung cancer and high BMI.^[21] In any case, both studies support the use of baseline BMI as a stratification factor in future ICIs trials. Third, HCC patients with high tumor load as reflected by total tumor volume, tumor burden score, and α -fetoprotein levels^[19,22] were more likely to benefit from combination therapy. Fourth, the statistical significance of CK19 expression as a biomarker may be achieved when included larger sample size. Actually, the expression of CK19 is a biomarker among patients with HCC after hepatic resection or after regorafenib therapy.^[23-25] Therefore, these variables may also serve as predictors of efficacy of combination therapy in patients with advanced HCC.

In conclusion, lenvatinib plus ICIs therapy seems to be more effective in advanced HCC patients with viral etiology, low BMI, or high tumor load.

Disclosures

Ethics Committee Approval: This study was approved by the institutional review board of Guangxi Medical University Cancer Hospital (number LW2021026).

Conflict of Interest Disclosures: Dr Papatheodoridis has served as lecturer/advisor for Bayern, Ipsen and Roche; the other authors have nothing to disclose.

Funding/Support: J.-H.Z is in part supported by 'Guangxi BaGui Scholars' Special Fund (2019AQ20) and the Guangxi Science and Technology Base and Talents Special Project (2021AC19370).

Role of the Funder/Sponsor: The funding organizations had no role in the design and conduct of the study; collection, management, analysis, and interpretation of the data; preparation, review, or approval of the manuscript; and decision to submit the manuscript for publication.

Disclaimer: This article's contents are solely the responsibility of the authors.

Authorship Contributions: Concept – J.-H.Z.; Design – J.-H.Z.; Supervision – B.-D.X., L. M.; Materials – Y.-X.T., P.-P.G., K.-Z.Q., K.C., G.P., B.-D.X., L.M., J.-H.Z.; Data collection & processing – Y.-X.T., P.-P.G., K.-Z.Q., K.C., G.P., B.-D.X., L.M., J.-H.Z.; Analysis and interpretation – Y.-X.T., J.-H.Z.; Literature search – J.-H.Z.; Writing – Y.-X.T., J.-H.Z.; Critical review – J.-H.Z., G.P.

References

- Ren Z, Xu J, Bai Y, Xu A, Cang S, Du C, et al. Sintilimab plus a bevacizumab biosimilar (IBI305) versus sorafenib in unresectable hepatocellular carcinoma (ORIENT-32): a randomised, open-label, phase 2-3 study. *Lancet Oncol* 2021;22:977–90.
- Finn RS, Ikeda M, Zhu AX, Sung MW, Baron AD, Kudo M, et al. Phase Ib study of lenvatinib plus pembrolizumab in patients with unresectable hepatocellular carcinoma. *J Clin Oncol* 2020;38:2960–70.
- Lan XB, Papatheodoridis G, Teng YX, Zhong JH. The upward trend in the immunotherapy utilization for hepatobiliary cancers. *Hepatobiliary Surg Nutr* 2021;10:692–5.
- Deng ZJ, Li L, Teng YX, Zhang YQ, Zhang YX, Liu HT, et al. Treatments of hepatocellular carcinoma with portal vein tumor thrombus: current status and controversy. *J Clin Transl Hepatol* 2022;10:147–58.
- Liu HT, Jiang MJ, Deng ZJ, Li L, Huang JL, Liu ZX, et al. Immune checkpoint inhibitors in hepatocellular carcinoma: current progresses and challenges. *Front Oncol* 2021;11:737497.
- Finn RS, Qin S, Ikeda M, Galle PR, Ducreux M, Kim TY, et al. Atezolizumab plus bevacizumab in unresectable hepatocellular carcinoma. *N Engl J Med* 2020;382:1894–905.
- Yau T, Park JW, Finn RS, Cheng AL, Mathurin P, Edeline J, et al. CheckMate 459: A randomized, multi-center phase III study of nivolumab (NIVO) vs sorafenib (SOR) as first-line (1L) treatment in patients (pts) with advanced hepatocellular carcinoma (aHCC). *Ann Oncol* 2019;30:v874–5.

8. Finn RS, Ryoo BY, Merle P, Kudo M, Bouattour M, Lim HY, et al. Pembrolizumab as second-line therapy in patients with advanced hepatocellular carcinoma in KEYNOTE-240: a randomized, double-blind, phase III trial. *J Clin Oncol* 2020;38:193–202.
9. Pfister D, Nunez NG, Pinyol R, Govaere O, Pinter M, Szydlowska M, et al. NASH limits anti-tumour surveillance in immunotherapy-treated HCC. *Nature* 2021;592:450–6.
10. Liu L, Xie S, Teng YX, Deng ZJ, Chen K, Liu HT, et al. Outcomes of liver resection for metabolic dysfunction-associated fatty liver disease or chronic hepatitis B-Related HCC. *Front Oncol* 2021;11:783339.
11. Rimini M, Kudo M, Tada T, Shigeo S, Kang W, Suda G, et al. Non-alcoholic steatohepatitis in hepatocarcinoma: new insights about its prognostic role in patients treated with lenvatinib. *ESMO Open* 2021;6:100330.
12. Chin KM, Prieto M, Cheong CK, Di Martino M, Ielpo B, Goh BKP, et al. Outcomes after curative therapy for hepatocellular carcinoma in patients with non-alcoholic fatty liver disease: a meta-analysis and review of current literature. *HPB (Oxford)* 2021;23:1164–1174.
13. Wu H, Li Y, Shi G, Du S, Wang X, Ye W, et al. Hepatic interferon regulatory factor 8 expression suppresses hepatocellular carcinoma progression and enhances the response to anti-programmed cell death protein-1 therapy. *Hepatology*. 2022 Jan 6. Doi: 10.1002/hep.32316. [Epub ahead of print].
14. Xiang J, Zhang N, Sun H, Su L, Zhang C, Xu H, et al. Disruption of SIRT7 increases the efficacy of checkpoint inhibitor via MEF2D regulation of programmed cell death 1 Ligand 1 in Hepatocellular Carcinoma cells. *Gastroenterology* 2020;158:664–78.e24.
15. Kurebayashi Y, Ojima H, Tsujikawa H, Kubota N, Maehara J, Abe Y, et al. Landscape of immune microenvironment in hepatocellular carcinoma and its additional impact on histological and molecular classification. *Hepatology* 2018;68:1025–41.
16. Moldogazieva NT, Zavadskiy SP, Sologova SS, Mokhosoev IM, Terentiev AA. Predictive biomarkers for systemic therapy of hepatocellular carcinoma. *Expert Rev Mol Diagn* 2021;21:1147–64.
17. Chen K, Wei W, Liu L, Deng ZJ, Li L, Liang XM, et al. Lenvatinib with or without immune checkpoint inhibitors for patients with unresectable hepatocellular carcinoma in real-world clinical practice. *Cancer Immunol Immunother*. 2021 Sep 24. doi: 10.1007/s00262-021-03060-w. [Epub ahead of print].
18. Eslam M, Newsome PN, Sarin SK, Anstee QM, Targher G, Romero-Gomez M, et al. A new definition for metabolic dysfunction-associated fatty liver disease: An international expert consensus statement. *J Hepatol* 2020;73:202–9.
19. Sasaki K, Morioka D, Conci S, Margonis GA, Sawada Y, Ruzzenente A, et al. The tumor burden score: a new "Metro-ticket" prognostic tool for colorectal liver metastases based on tumor size and number of tumors. *Ann Surg* 2018;267:132–41.
20. Toso C, Trotter J, Wei A, Bigam DL, Shah S, Lancaster J, et al. Total tumor volume predicts risk of recurrence following liver transplantation in patients with hepatocellular carcinoma. *Liver Transpl* 2008;14:1107–15.
21. Kichenadasse G, Miners JO, Mangoni AA, Rowland A, Hopkins AM, Sorich MJ. Association between body mass index and overall survival with immune checkpoint inhibitor therapy for advanced non-small cell lung cancer. *JAMA Oncol* 2020;6:512–8.
22. Hsu CY, Huang YH, Hsia CY, Su CW, Lin HC, Loong CC, et al. A new prognostic model for hepatocellular carcinoma based on total tumor volume: the Taipei Integrated Scoring System. *J Hepatol* 2010;53:108–17.
23. Zhuo J, Lu D, Lin Z, Yang X, Yang M, Wang J, et al. The distinct responsiveness of cytokeratin 19-positive hepatocellular carcinoma to regorafenib. *Cell Death Dis* 2021;12:1084.
24. Zhang J, Qi YP, Ma N, Lu F, Gong WF, Chen B, et al. Overexpression of Epcam and CD133 Correlates with Poor Prognosis in Dual-phenotype Hepatocellular Carcinoma. *J Cancer* 2020;11:3400–6.
25. Obiorah IE, Chahine J, Ko K, Park BU, deGuzman J, Kallakury B. Prognostic implications of arginase and cytokeratin 19 expression in hepatocellular carcinoma after curative hepatectomy: correlation with recurrence-free survival. *Gastroenterology Res* 2019;12:78–87.