



Case Report

A Rare Clinical Presentation of Neurobrucellosis Paraparesis: A Report of two Cases

 Gokhan Ozer,¹  Gulnihal Kutlu,²  Levent Ertugrul Inan³

¹Department of Neurology, Sanko University Faculty of Medicine, Gaziantep, Turkey

²Department of Neurology, Mugla Sitki Kocman University Faculty of Medicine, Mugla, Turkey

³Department of Neurology, Bozok University Faculty of Medicine, Yozgat, Turkey

Abstract

Brucellosis is a common infectious disease that is common in Turkey, as in other Mediterranean countries. It is a zoonosis that humans contract by either direct contact with infected animals or ingestion of raw meat or unpasteurized milk from such animals. It causes various symptoms, such as muscle and joint pains and headache. Neurobrucellosis may cause paresis, neuritis, meningoencephalitis, myelitis, psychosis, and rarely Guillain–Barré syndrome. Diagnosis of brucellosis is difficult owing to the nonspecific symptoms of the disease. A definite diagnosis was made by the isolation of the microorganism from the blood, cerebrospinal fluid, bone marrow, and other tissues. We discuss two cases with paraparesis due to brucellosis.

Keywords: Brucellosis, myelitis, neurobrucellosis, paraparesis.

Cite This Article: Ozer G, Kutlu G, Inan L. A Rare Clinical Presentation of Neurobrucellosis Paraparesis: A Report of two Cases. *EJMO*. 2018; 2(4): 254-257

Symptoms of brucellosis consist of headache, rheumatism pains, high fever, and chronic fatigue. Direct central nervous system (CNS) involvement is rare, occurring <5% of adult cases and <1% of pediatric cases.^[1] In acute infections, neurological involvement is not specific, and headache, fatigue and myalgia are observed. Chronic neurobrucellosis occurs in 5-10% of diagnosed case.^[2] These have included myelitis, meningoencephalitis, meningomyelitis, optic neuritis, peripheral neuritis, cranial nerve paralysis. Involvement cranial or peripheral nerves alone or in combination is observed.^[2-7]

The diagnosis of neurobrucellosis is based on cerebrospinal fluid (CSF) findings (Lymphocytic pleocytosis with abnormally high protein level and positive titer of STA and/or positive culture).

Patients with brucellosis are admitted to the hospital with

different clinical presentation. Polyradiculoneuritis is one of that. Demyelination in spinal tracts and peripheral nerves have been reported.^[2] Polyradiculitis is presented as a slow progress flaccid paralysis. This usually involves legs only. The upper limb is rarely affected.^[3]

Myelitis may be also another clinical sign of neurobrucellosis. The incidence of acute transverse myelitis is 1-4/1 million and this may occur in every age and mostly seen in second and fourth decade. Family history or sex differences do not influence the incidence of the disease. Transverse myelitis may be caused by vascular malformations, aneurysm and aneurismal rupture, demyelinating disorders, radiation, malignant diseases, vaccines, Systemic Lupus Erythematosus, infections (polio, echovirus, coxsackie, measles, chicken pox, mumps, rabies, typhoid, syphilis, brucellosis) and heroin abuse. Two cases with paraparesia was caused by brucellosis were reported in this article.

Address for correspondence: Gokhan Ozer, MD. Sanko Universitesi Tip Fakultesi Noroloji Anabilim Dalı, Gaziantep, Turkey

Phone: +90 342 211 53 12 **E-mail:** primernordr@gmail.com

Submitted Date: September 21, 2017 **Accepted Date:** October 31, 2017 **Available Online Date:** October 10, 2018

©Copyright 2018 by Eurasian Journal of Medicine and Oncology - Available online at www.ejmo.org



Case Report

Case 1 – A 56 year-old-woman represented with the weakness of lower extremities. This symptom started one and a half month ago and increased progressively. This patient was admitted to our hospital and the etiology of paraparesia was evaluated. Cholecystectomy operation was present in her medical history. There was no abnormality in her physical examination. She had a history of unboiled milk ingestion. Complete blood count, liver function tests, coagulation parameters, kidney function tests, plasma electrolytes, plasma lipid levels, serum vitamin B12 and folic acid, thyroid function test, CRP (C-reactive protein), RF(rheumatoid factor), ASO (Antistreptolysin O), ANA (antinuclear antibodies), Anti ds-DNA(anti-double-stranded

DNA antibodies), VDRL (Venereal Diseases Research Laboratory) test, TPHA (Treponema pallidum haemagglutination), the screen of hepatitis markers, direct and indirect coombs test were normal. The neurological examination of this patient revealed paraparesia. Deep tendon reflexes were absent. Cervical and thoracic MRI were normal. Lumbosacral MRI revealed diffuse bulging in L3-4, L4-5 and L5-S1. Gadolinium was not used in MRI imaging because of allergy.

Polyradiculoneuritis was determined in electrophysiological investigations. The findings of nerve conduction studies before treatment are shown in Table 1a and b. Denervation potentials were observed in right and left extensor digitorum brevis, tibialis anterior, L2, L3, L4, L5 and S1 paraspinal and right medial gastrocnemius muscles.

The etiology of Polyradiculoneuritis was investigated after this electrophysiological study. Standard tube agglutination testing (STA) titers was 1/320 in the serum. Brucella IgM was negative while brucella IgG and Rose- Bengal test was positive in the serum. Lumbar puncture was planned after positive standard tube agglutination testing of brucella. The glucose, chloride and protein levels in CSF were 50 mg/dL, 117 mmol/dl, and 327 mg/dL respectively. In direct microscopic examinations of CSF, 940/mm³ new erythrocytes, 810/mm³ leukocytes (65% polymorphonuclear leukocytes and 35% mononuclear leukocytes) were seen. Standard tube agglutination testing (STA) titers was 1/64 in the CSF, but the microorganism was not isolated in CSF culture.

After these investigations, neurobrucellosis was diagnosed and antibrucellosis treatment was begun (Ceftriaxone 2x2 g, Rifampicin 1x600 mg and doxycycline 2x100 mg). The neurological examination after ten days of treatment revealed mild recovery in paraparesia. The lumbar puncture was repeated after one week and one month of antibrucel-

Table 1a. Motor nerve conduction studies before treatment

| Right | DL (msec) | Vel (m/sec) | Amp (mV) | F Larency |
|---------------------|--------------|----------------|-------------|--------------|
| N. medianus | 3.3 | 45.5 | 6.0 | 26.5 |
| N. ulnaris | 3.1 | 54 | 7.8 | 28.3 |
| N. peroneus | 5.8* | 35.4* | 3.9* | 55.6* |
| N. posterior tibial | 6.0* | 38.1* | 4.9* | 60.5* |

*pathological values.

Table 1b. Sensory nerve conduction studies before treatment

| Right | | Vel (m/sec) | Amp (mV) |
|------------|-------|-------------|----------|
| N. median | 2.F-W | 31.1* | 11.2* |
| N. ulnaris | 5.F-W | 35.6* | 6.5* |
| N. suralis | | 26.5* | 7.6* |

*pathological values; DL: Distal latency; Vel: Velocity; Amp: Amplitude; F-W: Finger-Wrist; N: Nervus.

Table 2. CSF findings

| | First LP | After one week | After one month |
|---------------------------------|------------------|------------------|------------------|
| Pressure | Normal | Normal | Normal |
| Appearance | Blurred | Mildly blurred | Normal |
| Leukocyte (/mm ³) | 810 | 690 | 70 |
| Erythrocyte (/mm ³) | 940 (new) | - | - |
| Leukocyte distribution | 65% PMNL | %99 Lymphocyte | %100 Lymphocyte |
| Gram staining | No microorganism | No microorganism | No microorganism |
| Protein (mg/dl) | 51 | 15 | 50 |
| Blood glucose (mg/dl) | 98 | 112 | 77 |
| Chloride (mg/dl) | 117 | 115 | 117 |
| CSF | - | - | - |
| STA | 1/8 | 1/32 | 1/64 |
| Brucella IgM | + | + | + |
| Rose bengal | + | - | - |

Table 3. Sensory nerve conduction studies three months

| Right | | Vel (m/sec) | Amp (mV) |
|------------|-------|-------------|----------|
| N. median | 2.F-W | 31.5 | 14.5 |
| N. ulnaris | 5.F-W | 49.6 | 8.8 |
| N. suralis | | 43.2 | 14.0 |

losis treatment. The CSF findings are shown in Table 2.

The electrophysiological investigation and the neurological examination of the patient were normal after three months of treatment. Table 3 represents the electrophysiological studies after three months of the treatment.

Case 2 – A 26 year-old-man was admitted to our hospital with difficulty of walking in two and a half years. At the time of admission he had a weakness of lower extremities and hypoesthesia up to the lower chest while only mild gait disturbance was present at the beginning of the disease. Urinary and fecal incontinence was also seen. He had a history of unboiled milk ingestion. In his medical history brucellosis was diagnosed and treated three years ago. Paraparesia (2/5), hyperactive deep tendon reflexes, hypoesthesia under T10 level, decrease of vibration and joint position in right lower extremities absence of abdominal reflexes and extensor plantar responses were determined in his neurological examination at the time of admission.

Complete blood count, liver function tests, coagulation parameters, kidney function tests, plasma electrolytes, plasma lipid levels, serum vitamin B12 and folate, thyroid function test, CRP, RF, ASO, ANA, Anti ds-DNA, VDRL, TPHA, the screen of hepatitis markers, CMV IgG, Toxoplasmosis IgG, Anti-HIV were normal. Since he had brucellosis in his medical history, in his evaluated blood test. Standard tube agglutination testing (STA) titers was 1/320 in the serum. Brucella IgM was negative while brucella IgG and Rose-Bengal test was positive in the serum.

Cranial and Lumbosacral MRI were normal. Thorocal spinal MRI revealed demyelinating plaque at the level of T8-10 (Fig. 1) and transverse myelitis was diagnosed according to the MRI and clinical findings. Lumbar puncture was done after the determination of this thorocal MRI lesion. The glucose, chloride and protein level in CSF were 29 mg/dl, 121 mmol/dl, 206 (Normal: 15-45 mg/dl) mg/dL respectively. The direct microscopic examination of CSF was normal. Standard tube agglutination testing (STA) titers was 1/64 in the CSF, but the microorganism was not isolated in CSF culture. Oligoclonal band was positive in CSF and IgG index was also increased. Nerve conduction study of patient was normal and there was no response in posterior tibial somatosensorial evoked potentials (SEP). After all these

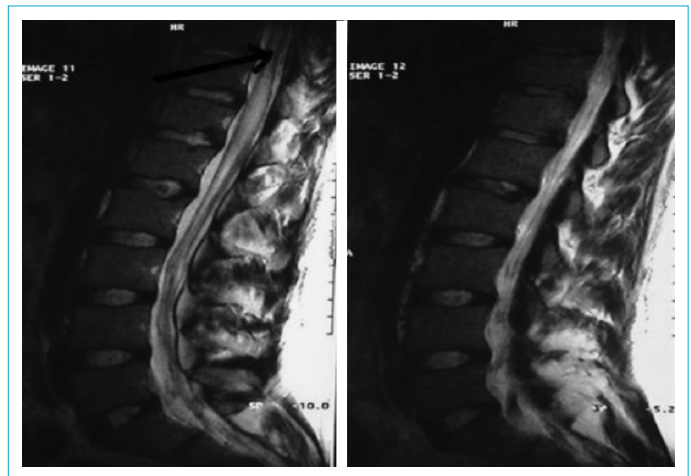


Figure 1. Spinal Thoracal MRI T2-weighted sagittal image shows linear high signal intensity mild cord swelling in T8-T10 level.

investigations, we thought that the etiology of transverse myelitis was Brucella organism. Prednisolone 1000 mg/day was given to the patients during five days and antibrucellosis treatment was started Ceftriaxone 2x2 g, Rifampicin 1x600 mg and Doxycycline 2x100 mg).

Discussion

Brucellosis constitutes major public health and economic problem in many countries around the world where the control measures are lacking. The clinical presentation of brucellosis is heterogeneous.^[3] The clinician should suspect especially in endemic areas and should perform the diagnostic tests. The most common infectious organism is Brucella melitensis.^[8]

Brucellosis was divided into four according to the incubation period: asymptomatic, acute, subacute, and chronic. Fatigue, headache, weakness, tiredness and arthralgias were observed in acute period of the disease. If the symptoms were continued at least one year, chronic period of the disease will start and neurological and psychiatric signs will be seen in this period. The complication of brucellosis consists of sacro-ileitis (20-30%), genito-urinary system involvement (2-40%), neurobrucellosis especially meningitis (1-2%) and endocarditis (1%).^[1] Headache, convulsion, hemiplegia, parkinsonism, psychosis, acute and chronic meningoencephalitis, myelitis, myelopathies, cranial neuropathies, radiculopathies, peripheral neuropathy, myositis, meningovascular disease, multifocal white matter disease, subdural abscess, subarachnoid hemorrhage, intracerebral or epidural abscess, intracranial hypertension, hydrocephalus, papilledema and mycotic aneurysm are the symptoms and signs of the neurobrucellosis.^[2]

Brucella organisms are capable of prolonged intracellular survival within phagocytes.^[2] The risk of neurobrucellosis

is increased due to the weakness of immune system. The differentiation of neurobrucellosis is difficult from the other chronic proliferate neurological diseases. Tuberculous meningitis, viral encephalitis, aseptic meningitis and cerebral malaria were kept in mind in the differential diagnosis of neurobrucellosis.

The diagnosis of neurobrucellosis is based on the clinical picture compatible with brucellosis, detection of specific antibodies by standard tube agglutination testing (STA) (*Brucella abortus*, Omega Diagnostics, UK) at $\geq 1/160$ titers or a four fold or greater rise in antibody titer in serum specimens drawn two to three weeks apart or positive blood and/or bone marrow culture by BACTEC 9050 (Becton, Dickinson and Company; Ireland). The diagnosis of neurobrucellosis was also based on the same criteria and having symptoms and signs of nervous system and cerebrospinal fluid (CSF) findings (lymphocytic pleocytosis with abnormally high protein level and positive titer of STA and/or positive culture.^[9]

In the treatment of neurobrucellosis, the combination treatment with rifampicin was given. These combinations: Doxycycline+Rifampicin+Streptomycin, Doxycycline+Rifampicin+Co-trimoxazole.^[5, 8] Duration of treatment was between 6 weeks and 6 months. However, the treatment should be continued until normal CSF protein, cell count $<100/\text{mm}^3$ and the beginning of the decrease in antibody titer in CSF.^[3, 10]

Case 1 and Case 2 had neurobrucellosis according to the clinical and laboratory findings. Two of our patients had paraparesia. Polyradiculoneuritis was determined in Case 1, antibrucellosis therapy was started and complete recovery was obtained after treatment. Case 2 had also paraparesia, but he had also some additional neurological abnormal findings such as hyperactive deep tendon reflexes, hypoaesthesia under T10. Transverse myelitis was determined and pulse steroid treatment was given besides antibrucellosis treatment. Some neurological sequels were observed in case 2.

The clinical presentation of two cases was interesting because they had only paraparesia at the time of admission to our hospital and they had no other symptoms of brucellosis. Case 1 had only lower motor neuron involvement while the other case had upper motor neuron involvement and hypoaesthesia under T10.

In conclusion, brucella organisms may cause various clinical and neurological symptoms and these symptoms were totally or partially cured after antibrucellosis treatment. Brucellosis may be considered as a cause of paraparesia either upper motor or lower motor neuron involvement especially in endemic areas.

Disclosures

Informed consent: Written informed consent was obtained from the patient for the publication of the case report and the accompanying images.

Peer-review: Externally peer-reviewed.

Conflict of Interest: None declared.

Authorship Contributions: Concept – G.O.; Design – G.O.; Supervision – L.E.I.; Materials – G.O., G.K.; Data collection &/or processing – G.O.; Analysis and/or interpretation – G.K.; Literature search – G.O.; Writing – G.O.; Critical review – L.E.I.

References

- Omar FZ, Zuberi S, Minns RA. Neurobrucellosis in childhood: six new cases and a review of the literature. *Dev Med Child Neurol* 1997;39:762–5. [\[CrossRef\]](#)
- al Deeb SM, Yaqub BA, Sharif HS, Phadke JG. Neurobrucellosis: clinical characteristics, diagnosis, and outcome. *Neurology* 1989;39:498–501. [\[CrossRef\]](#)
- Shakir RA. Neurobrucellosis. *Postgrad Med J* 1986;62:1077–9.
- Bucher A, Gaustad P, Pape E. Chronic neurobrucellosis due to *Brucella melitensis*. *Scand J Infect Dis* 1990;22:223–6. [\[CrossRef\]](#)
- Güven MB, Cirak B, Kutluhan A, Ugras S. Pituitary abscess secondary to neurobrucellosis. Case illustration. *J Neurosurg* 1999;90:1142. [\[CrossRef\]](#)
- Larbrisseau A, Maravi E, Aguilera F, Martinez-Lage JM. The neurological complications of brucellosis. *Can J Neurol Sci* 1978;5:369–76. [\[CrossRef\]](#)
- Ceviker N, Baykaner K, Göksel M, Sener L, Alp H. Spinal cord compression due to *Brucella granuloma*. *Infection* 1989;17:304–5. [\[CrossRef\]](#)
- Bouza E, García de la Torre M, Parras F, Guerrero A, Rodríguez-Créixems M, Gobernado J. Brucellar meningitis. *Rev Infect Dis* 1987;9:810–22. [\[CrossRef\]](#)
- Mousa AR, Koshy TS, Araj GF, Marafie AA, Muhtaseb SA, Al-Mudallal DS, et al. *Brucella meningitis: presentation, diagnosis and treatment-a prospective study of ten cases*. *Q J Med* 1986;60:873–85.
- Pascual J, Combarros O, Polo JM, Berciano J. Localized CNS brucellosis: report of 7 cases. *Acta Neurol Scand* 1988;78:282–9.